



# **OPTIMIZATION OF CORONARY CTA IMAGE QUALITY BY PIQE DEEP-LEARNING RECONSTRUCTION**

**Duong Phi Son, MS; Nguyen Tuan Vu, PhD; Phan Thanh Hai, MD**

*Department of Cardiology; Medic Medical Center, Vietnam.*

**I- INTRODUCTION**

**II- MATERIAL AND METHODS**

**III- RESULTS**

**IV- DISCUSSION**

**V- CONCLUSION**

# INTRODUCTION

- Cardiovascular disease (CVD) remains the leading cause of death worldwide.
- **Coronary artery disease (CAD)** is the most common type of cardiovascular disease.
- Most coronary artery disease can be prevented, if they are detected early and treated appropriately.
- Improve the prognosis and reducing the mortality rate.

## Test to help diagnosis or monitor coronary artery disease:

- Serum biomarkers (Cardiac Troponins).
- Chest X-Ray and ECG.
- Echocardiogram.
- Exercise stress test.
- Coronary artery CTA.
- Cardiac MRI.

- Computed tomography coronary angiography (CTA) is an emerging non-invasive tool for detecting significant coronary artery disease (CAD).
- Sensitivities and specificities of coronary CTA can compete with those of catheter angiography.

*Fleur R. de Graaf, MD. Ernst E. van der wall, MD, PhD. Diagnostic accuracy of 320-Row CT and challenging case scenarios.*

*De Graaf FR, Schuijf JD, van Velzen et al. Diagnostic accuracy of 320-Row multidetector computed tomography coronary angiography in the non-invasive evaluation of significant coronary artery disease.*

# 2019 ESC Guidelines on the diagnosis and management of chronic coronary syndromes



## What is new in the 2019 Guidelines?

### New recommendations (1)



#### Basic testing, diagnostics, and risk assessment

Non-invasive functional imaging or coronary CTA as the initial test for diagnosing CAD.

Initial non-invasive diagnostic test based on the clinical likelihood of CAD, patient characteristics, local expertise and availability.

Functional imaging for myocardial ischaemia if coronary CTA has shown CAD of uncertain functional significance or is not diagnostic.

Invasive angiography to diagnose CAD in patients with

- a high clinical likelihood and severe symptoms refractory to medical therapy
- typical angina at low level of exercise and clinical evaluation that indicates high event risk.

Invasive functional assessment must be available and used to evaluate stenoses before revascularization, unless very high grade (>90% diameter stenosis).

Invasive coronary angiography with availability of invasive functional evaluation for confirmation of CAD diagnosis in patients with uncertain diagnosis on non-invasive testing.

Coronary CTA as an alternative to invasive angiography if another non-invasive test is equivocal or non-diagnostic.

Coronary CTA when any conditions make good image quality unlikely.

■ Class I ■ Class IIa ■ Class IIb ■ Class III

- Currently, new generation CT scanner with deep-learning reconstruction, greatly improve the quality of coronary CTA image.
- **Precise IQ Engine (PIQE)** is super resolution deep-learning reconstruction technology trained with Ultra-High resolution (UHR) CT data.
- Deep-learning neural network allows PIQE to maximize the spatial resolution from volumetric scans.
- To provide a **new standard in coronary CT image quality.**

# PURPOSE

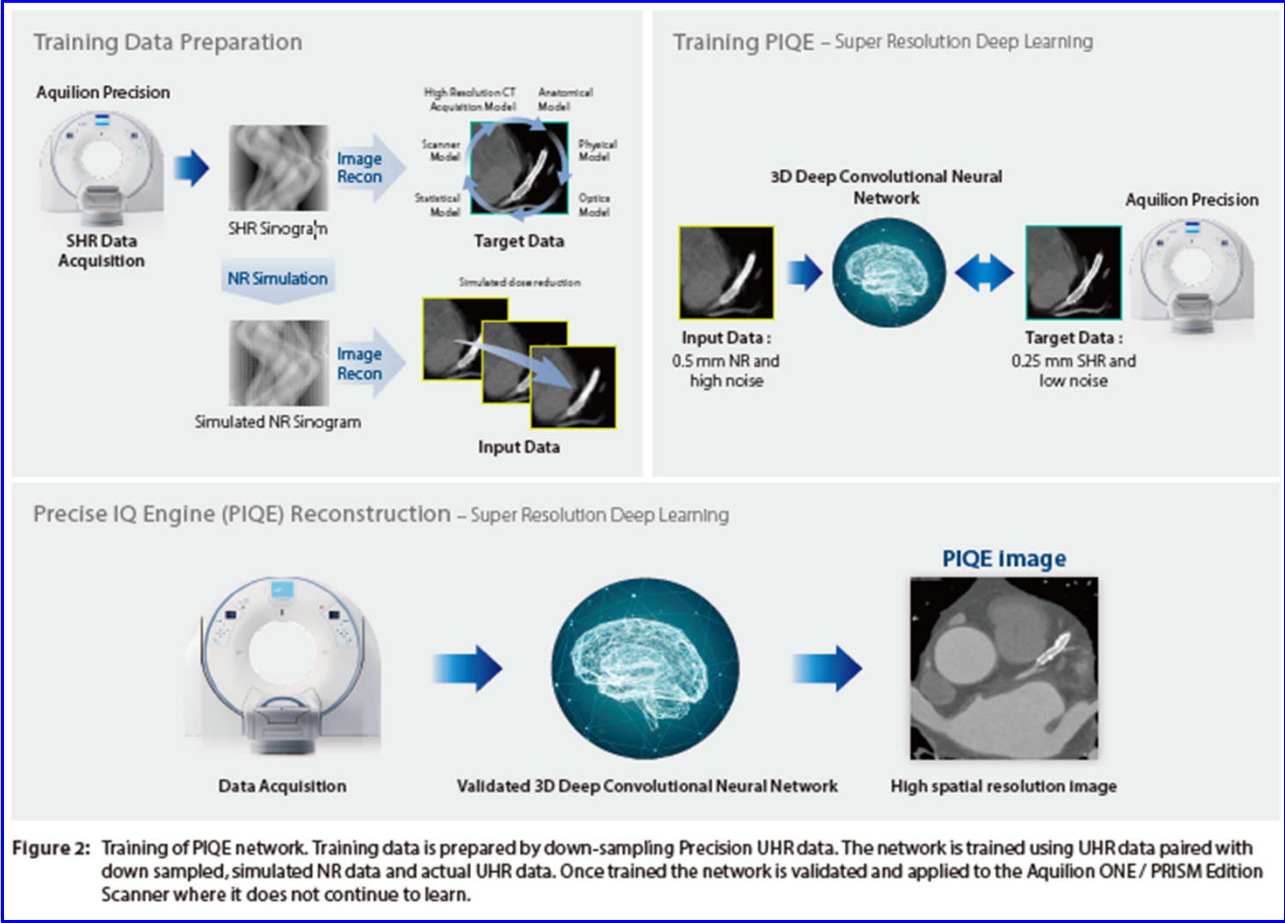
To compare the image quality from super resolution deep learning reconstruction (PIQE) with conventional hybrid iterative reconstruction (AIDR).

# MATERIAL AND METHODS

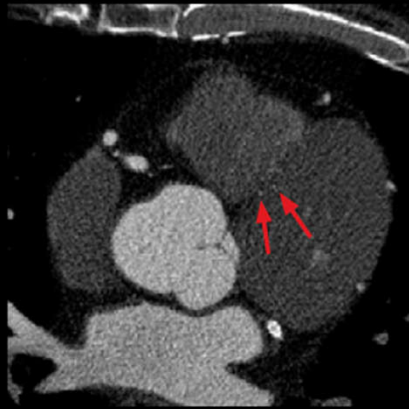- Since 01/07/2022 to 30/07/2022 in Medic Medical Center (Ho Chi Minh city, Vietnam), **101 patients** have been scanned coronary CTA by Aquilion ONE/PRISM Edition with PIQE reconstruction.
- A cross-sectional case control study.
- Statistical analysis by GraphPad and SPSS 22.0

- Coronary CT reports were reviewed by an experienced cardiothoracic radiologist and evaluated on a Likert scale (5=excellent, 1=poor) for:
- Signal to noise ratio (SNR), contrast to noise ratio (CNR), diagnostic confidence and overall image quality.
- All images were reconstructed with 0.5mm slice thickness.

# PIQE AI Training

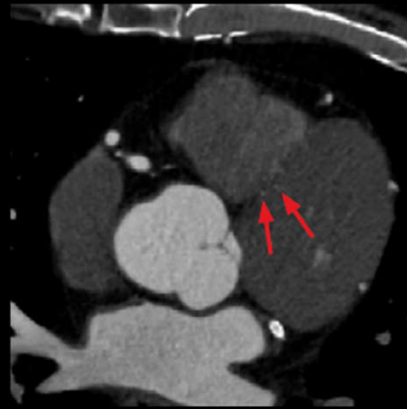

# 3D neural network in PIQE



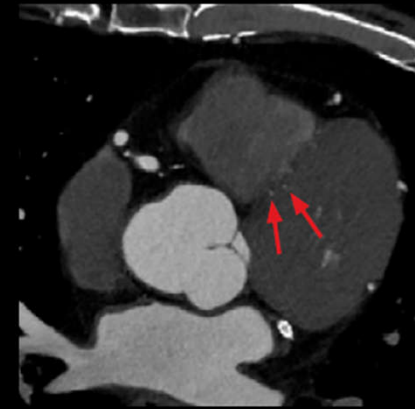
## **Before Denoising**

*Vessel is hard to differentiate  
with noise in a 2D slice*



## **2D Neural Network**

*Vessel difficult to visualize,  
reduced noise*



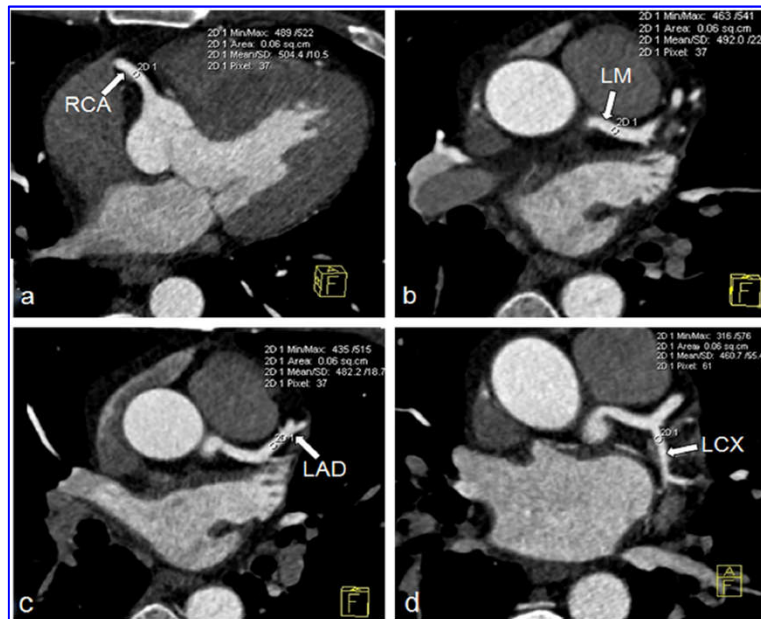
## **3D Neural Network**

*Vessel easy to visualize,  
reduced noise, improved sharpness*

*PIQE's three-dimensional learning helps ensure continuity in reconstruction of small, longitudinal vessels, often obscured by conventional reconstruction algorithms.*

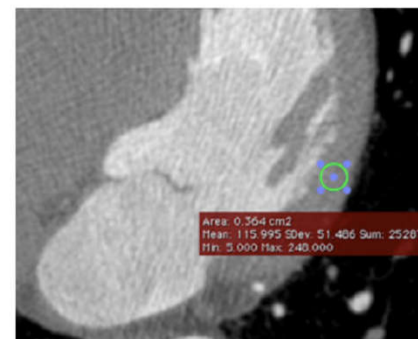
# To compare SNR and CNR between AIDR and PIQE

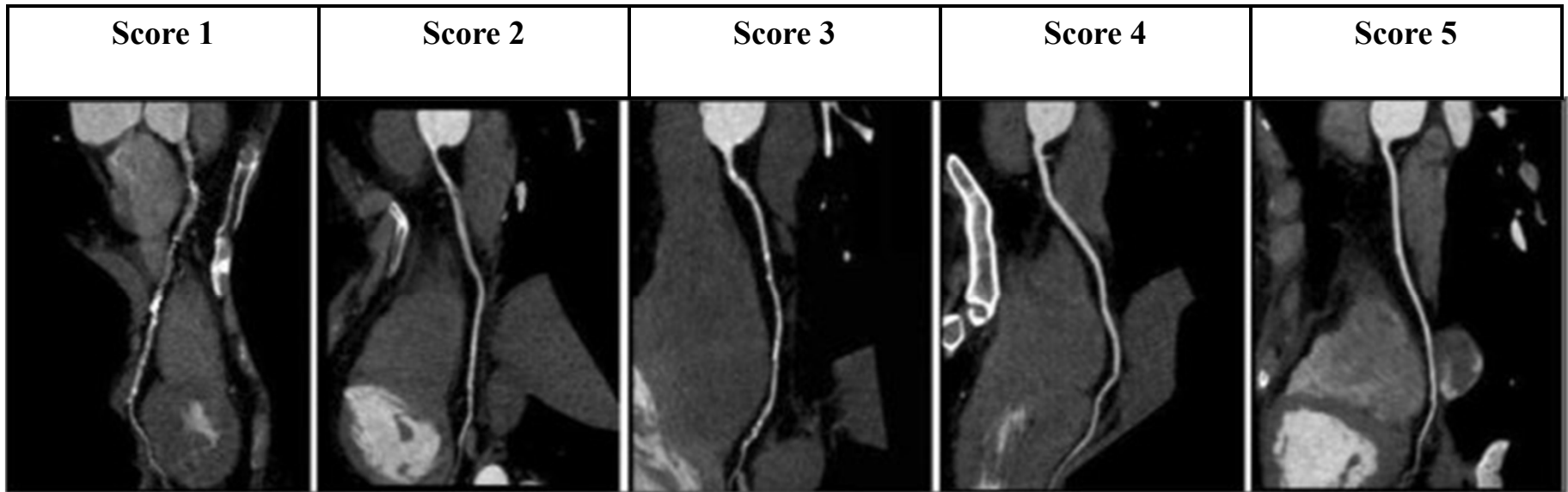
- ROI in ascending aorta, LM, proximal and distal RCA, LAD, LCX.
- The ROI will be different sizes due to different diameters of vessel.
- In axial cut, thickness 0.5mm in clinical review.



- Signal-to-noise ratio (SNR) =  $\frac{\text{Mean vascular density}}{\text{Mean SD of vascular density}}$

- Contrast-to-noise ratio (CNR) =  $\frac{\text{Mean vascular density} - \text{LV density}}{\text{Mean SD of vascular density}}$





Interval Range	Confidence Level
1.00–1.79	not confident at all
1.80–2.59	slightly confident
2.60–3.39	somewhat confident
3.40–4.19	fairly confident
4.20–5.00	completely confident

*Chong-fu Jia “Image quality and diagnostic value of ultra low-voltage, ultra low-contrast coronary CT angiography”*

# RESULTS AND DISCUSSION

## 1- General characteristics:

Characteristic	Frequencies (n=101)
Age	58 ± 10.9
Male ; Female	54( 53.4%) : 47(46.6%)

*Table 1.1*

BMI	Frequencies (n=101)
Underweight (BMI <18.5)	5 (5%)
Normal (BMI 18.5-25)	60 (59.4%)
Overweight (BMI >25)	36 (35.6%)

*Table 1.2*

## 2- The parameter of Overall image quality:

Overall image quality	PIQE	AIDR	P-value
Per vessel - LAD	4.96 ± 0.20	4.79 ± 0.41	< 0.01
Per vessel - LCX	4.91 ± 0.29	4.76 ± 0.41	< 0.01
Per vessel - RCA	4.96 ± 0.20	4.80 ± 0.40	< 0.01
Per vessel - PATIENT	4.99 ± 0.01	4.80 ± 0.40	< 0.01



Overall image quality for PIQE (4.99 ± 0.01) was **slightly higher than** AIDR (4.80 ± 0.40).

### 3- The parameter of noise characteristics:

Signal-to-Noise ratio (SNR)	PIQE	AIDR	P-value
Per vessel - LM	$26.2 \pm 7.8$	$15.7 \pm 4.4$	<0.0001
Per vessel - LAD	$22.4 \pm 7.9$	$13.2 \pm 3.6$	<0.0001
Per vessel - LCX	$22.2 \pm 8.2$	$13.7 \pm 4.4$	<0.0001
Per vessel - RCA	$23.3 \pm 7.4$	$13.7 \pm 3.8$	<0.0001
Per vessel - PATIENT	$33.5 \pm 4.7$	$20.4 \pm 3.4$	<0.0001



Signal-to-noise ratio for PIQE ( $33.5 \pm 4.7$ ) was **higher than** AIDR ( $20.4 \pm 3.4$ ).

#### 4- The parameter of noise characteristics:

Contrast-to-Noise ratio (CNR)	PIQE	AIDR	P-value
Per vessel - LM	21.4 ± 6.7	12.7 ± 3.9	<0.0001
Per vessel - LAD	18.2 ± 6.8	10.4 ± 3.2	<0.0001
Per vessel - LCX	17.8 ± 7.1	10.7 ± 3.7	<0.0001
Per vessel - RCA	19.0 ± 6.6	10.9 ± 3.4	<0.0001
Per vessel - PATIENT	27.9 ± 4.8	17.0 ± 3.5	<0.0001



Contrast-to-noise ratio for PIQE (27.9 ± 4.8) was **higher than** AIDR (17.0 ± 3.5).

## 5- The parameter of diagnostic confidence:

	PIQE	AIDR	P-value
<b>Diagnostic confidence</b>	$4.94 \pm 0.17$	$4.63 \pm 0.37$	$< 0.01$

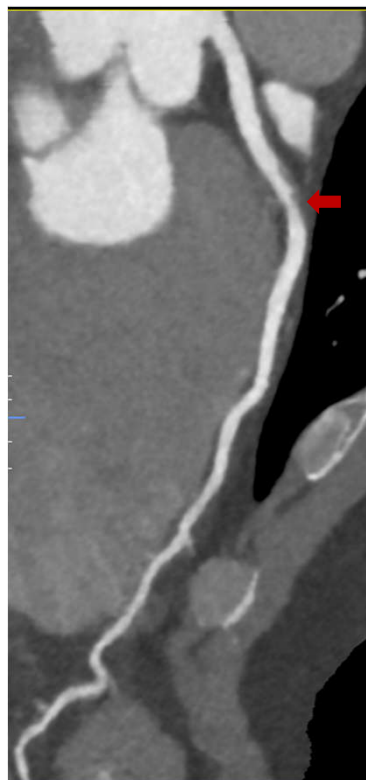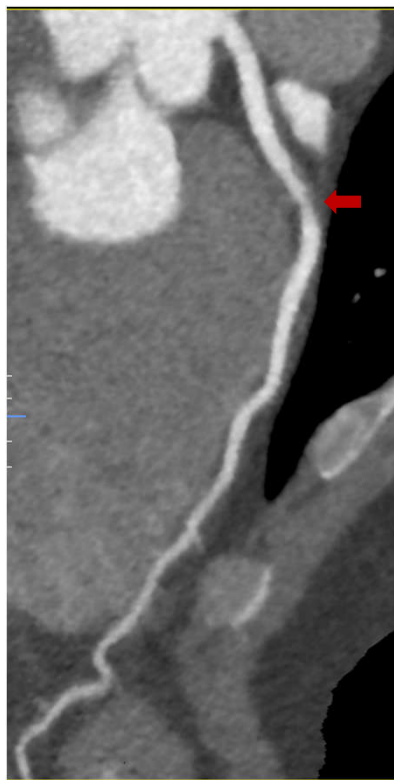


Diagnostic confidence **was improved** with PIQE ( $4.94 \pm 0.17$ ) over AIDR ( $4.63 \pm 0.37$ ).



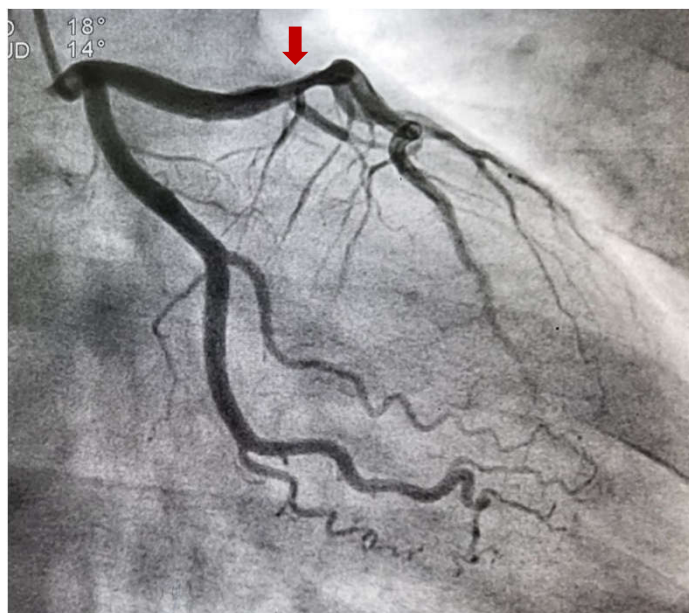
**AIDR**

**PIQE**

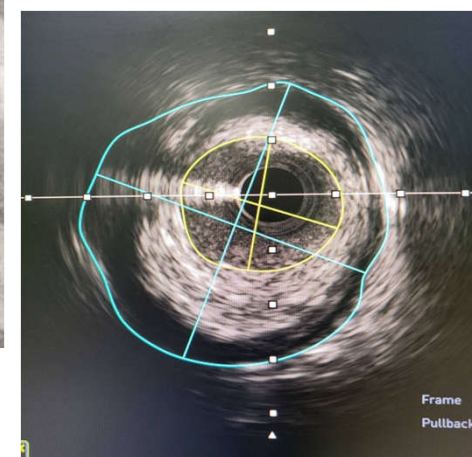
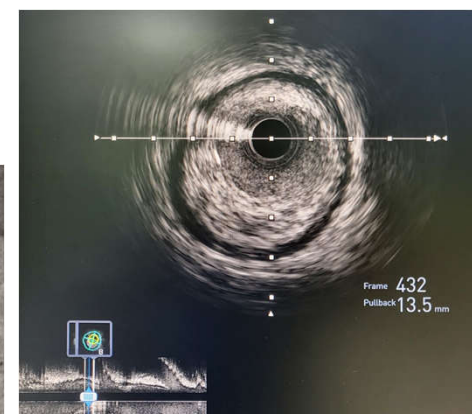


**LAD**

**LAD**

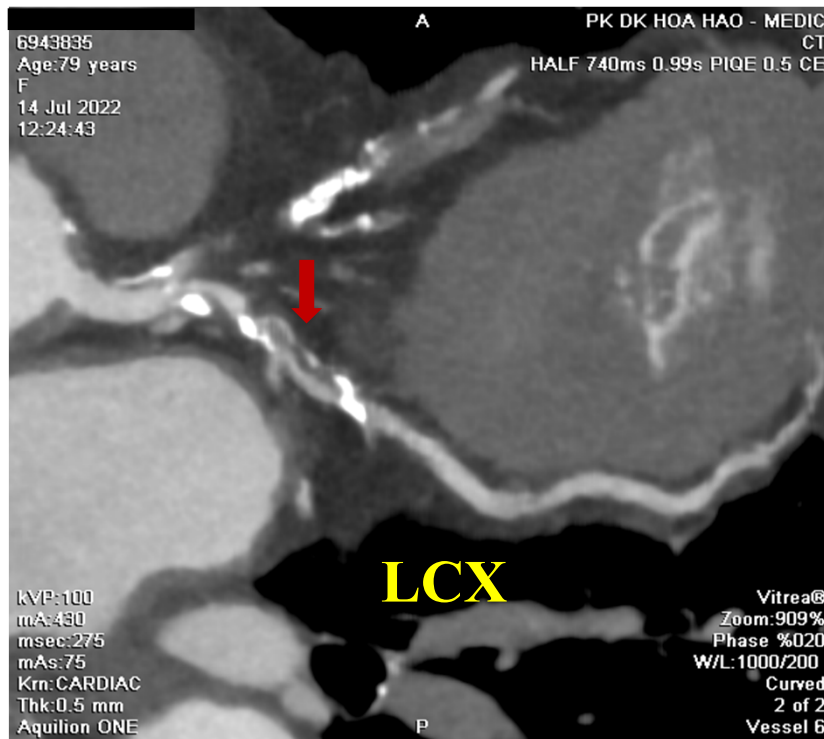


**Stenosis of 60-70% LAD I**

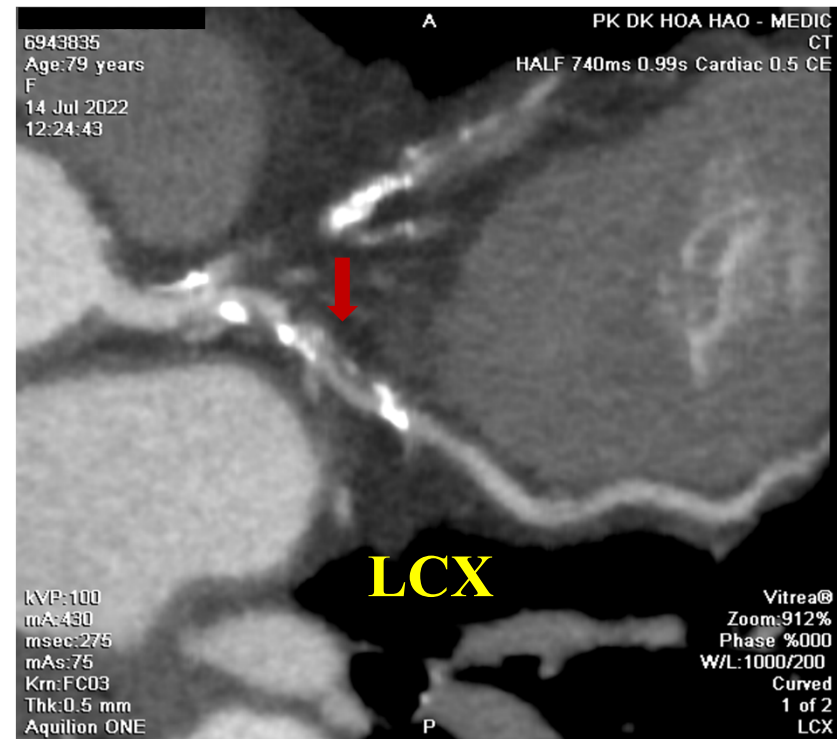


## Case 2:

Elderly women with diabetes mellitus, stenosis of 90% LCX I by mixed plaque, sharp and clearly visible lesion image by PIQE.



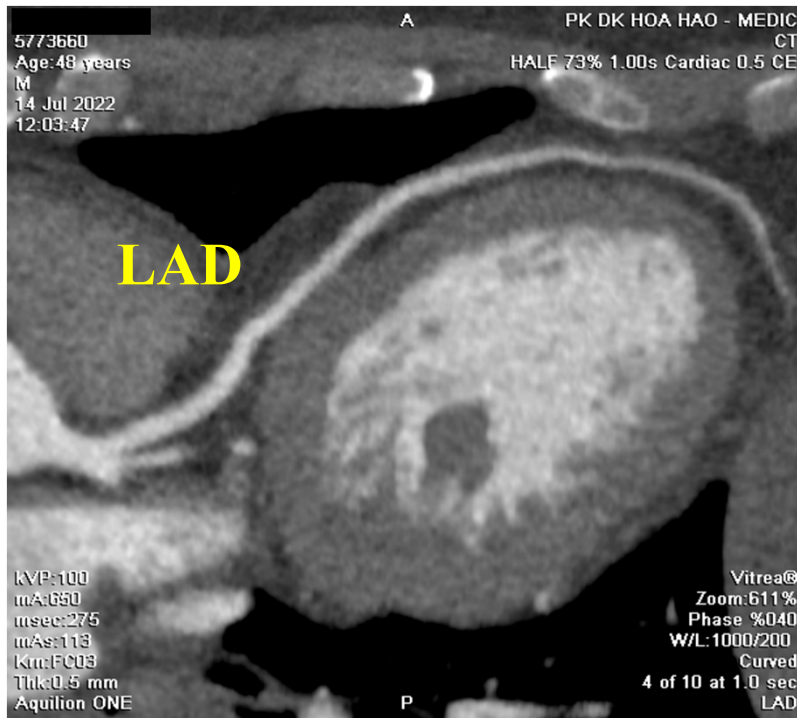
PIQE



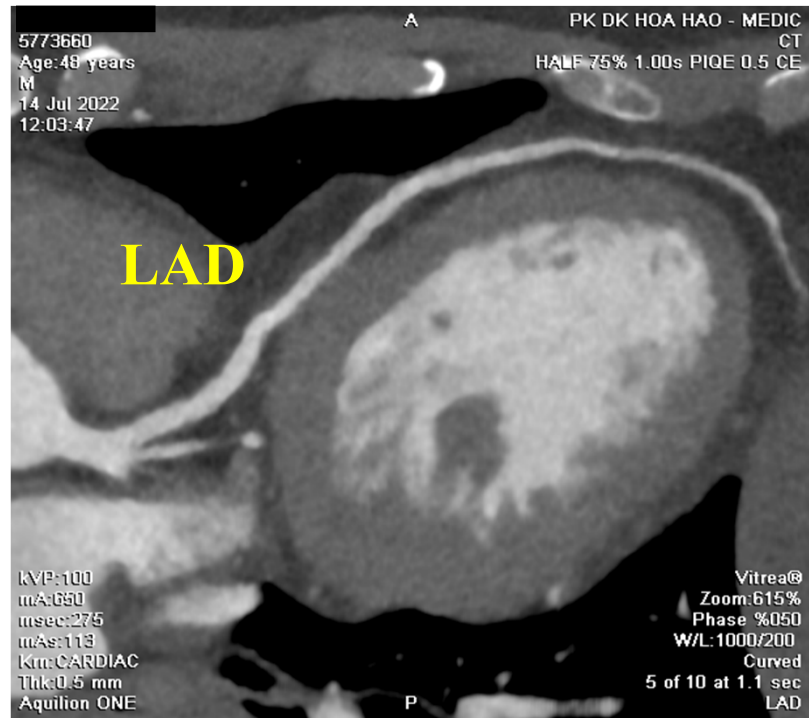
AIDR

## Case 3:

Young man, 39yrs, overweight (BMI=35) and smoking.



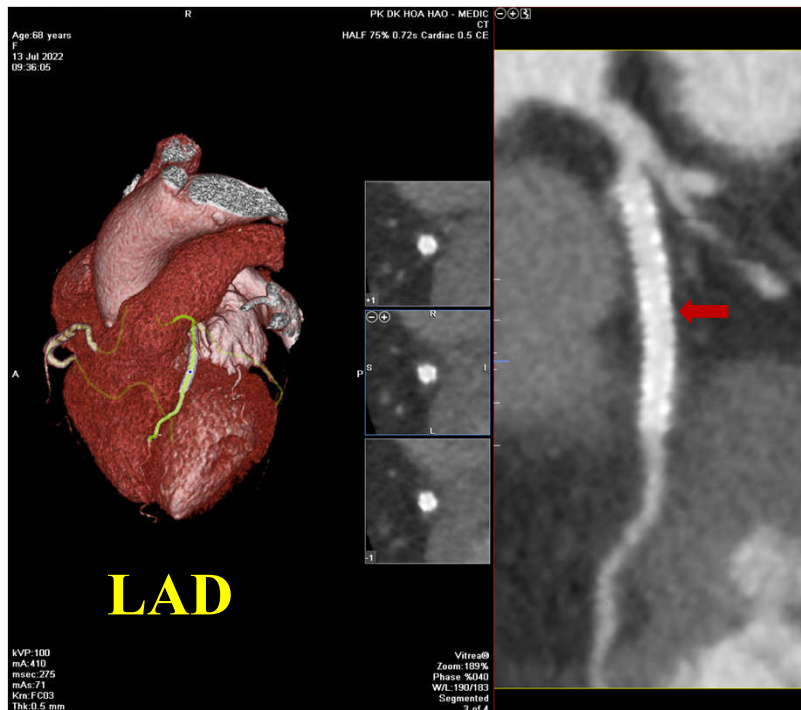
**AIDR**



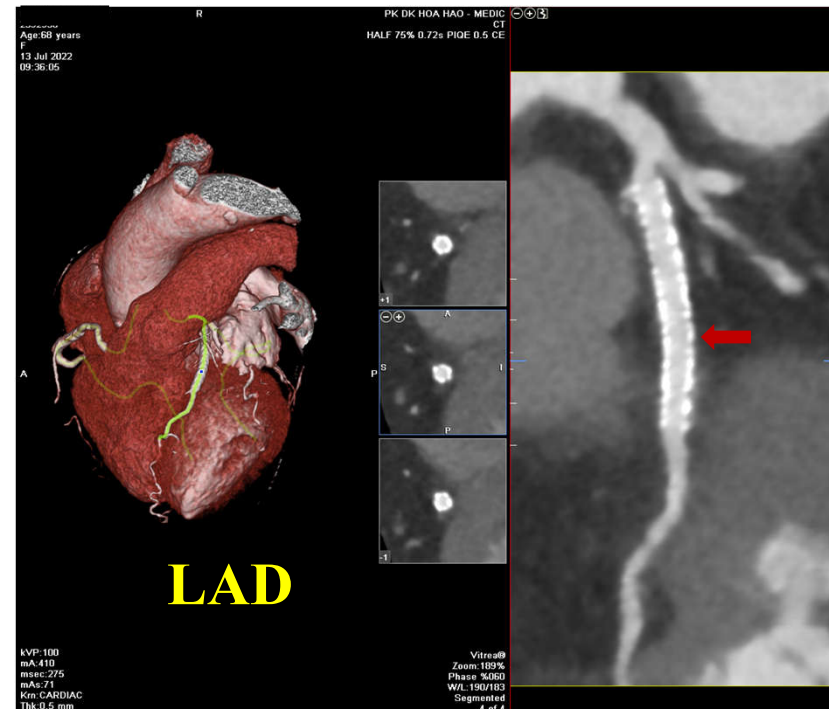
**PIQE**

## Case 4:

LAD stent is patency, stent blooming artefact from metallic stent struts will be reduced by PIQE.



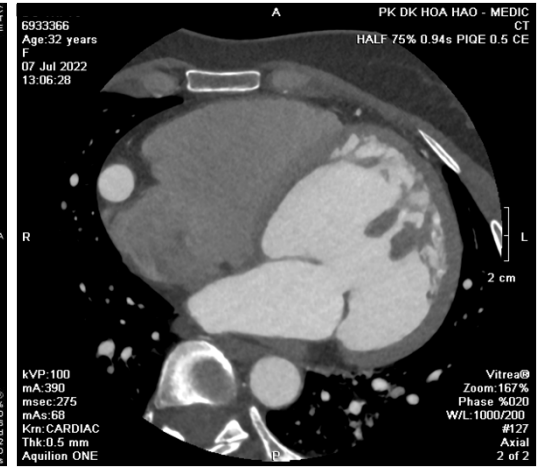
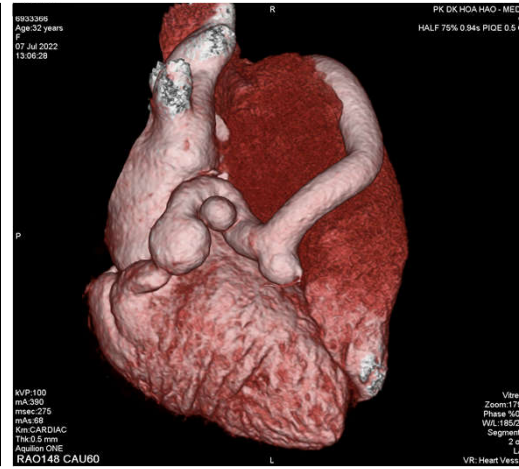
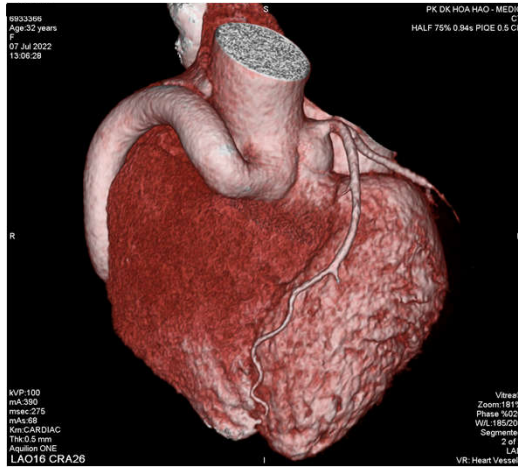
AIDR



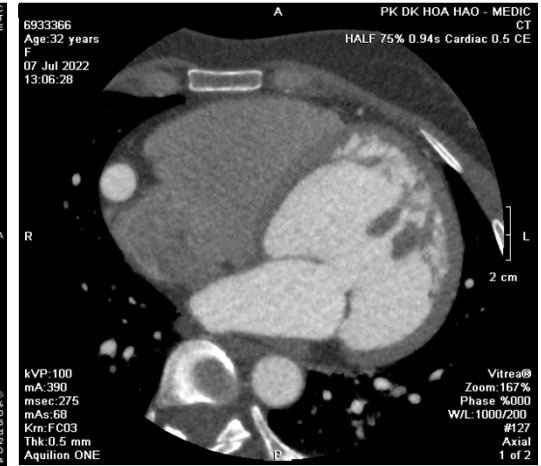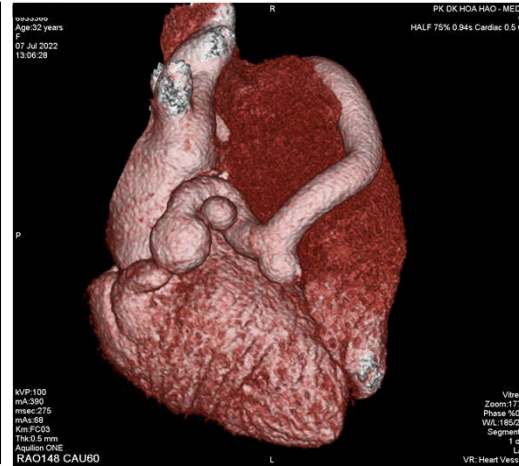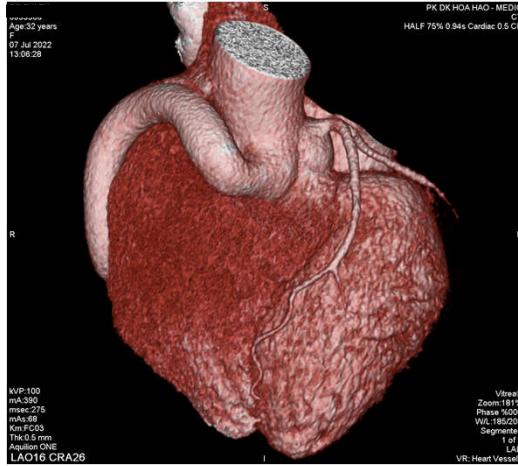
PIQE

# Case 5: Fistula from RCA to LV

PIQE



AIDR



# CONCLUSION

PIQE has improved spatial resolution, noise characteristics, diagnostic confidence and image quality compared to conventional reconstruction AIDR.



Thank you for your attention!