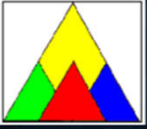



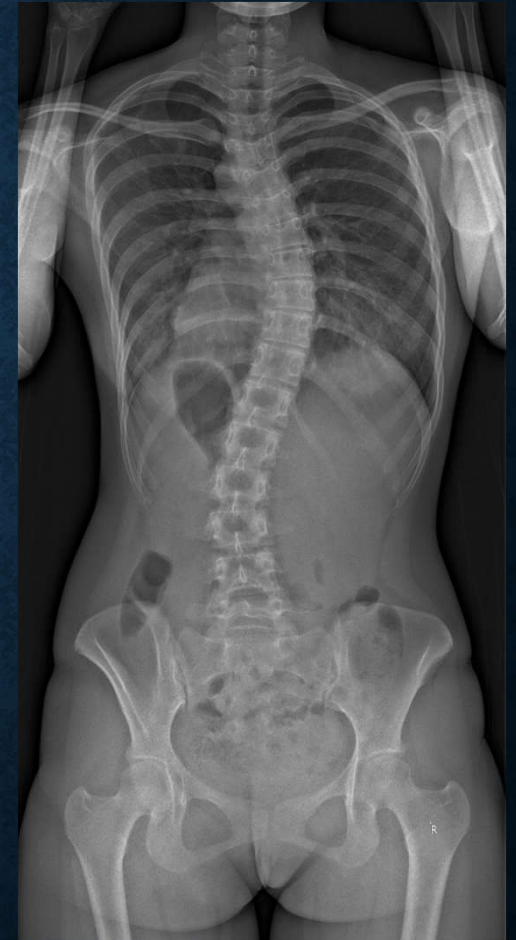# EOS CỘT SỐNG KẾT HỢP TUỔI XƯƠNG

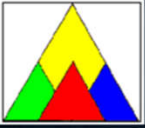BS. PHẠM THỊ CẨM VÂN



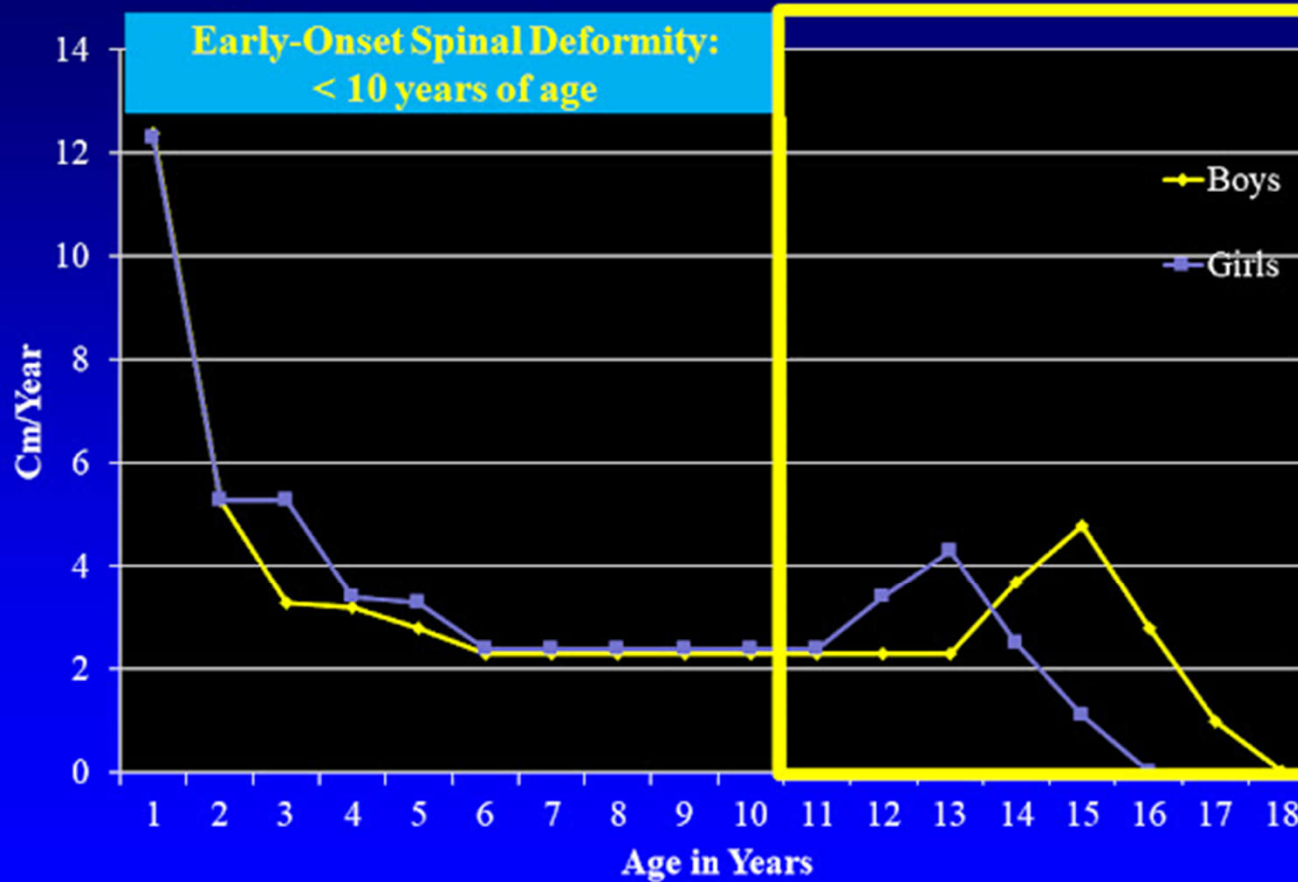
IDIOPATHIC SCOLIOSIS CAN BE CLASSIFIED BY AGE INTO:

1. ADOLESCENT IDIOPATHIC SCOLIOSIS (>11 YEARS)
2. JUVENILE IDIOPATHIC SCOLIOSIS (4-11 YEARS)
3. INFANTILE IDIOPATHIC SCOLIOSIS (<4 YEARS)





# Spine Growth in Childhood



Data from Dimeglio

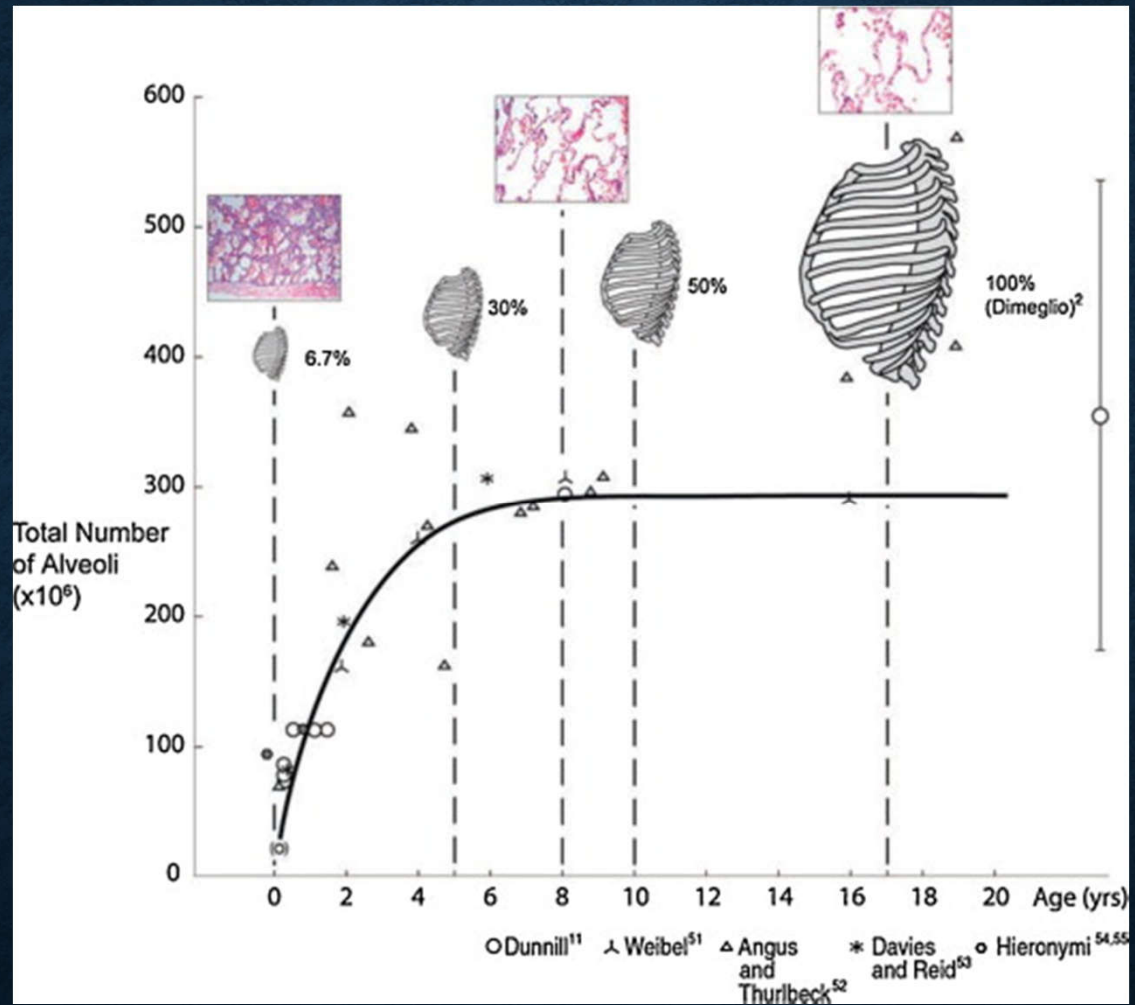


FIG. 2. ALVEOLAR GROWTH AND LUNG VOLUME AS A FUNCTION OF AGE, FROM [WITH PERMISSION



# MALE STANDARDS

## RADIOGRAPHIC ATLAS OF SKELETAL DEVELOPMENT OF THE HAND AND WRIST

**MALE  
STANDARDS**

**FEMALE  
STANDARDS**

**William Walter Greulich  
&  
S. Idell Pyle**

1 year

2 years

3 years

4 years

5 years

6 years

7 years

8 years

9 years

10 years

11 years

12 years

13 years

14 years

15 years

16 years

17 years

18 years



## Male: 11 Y

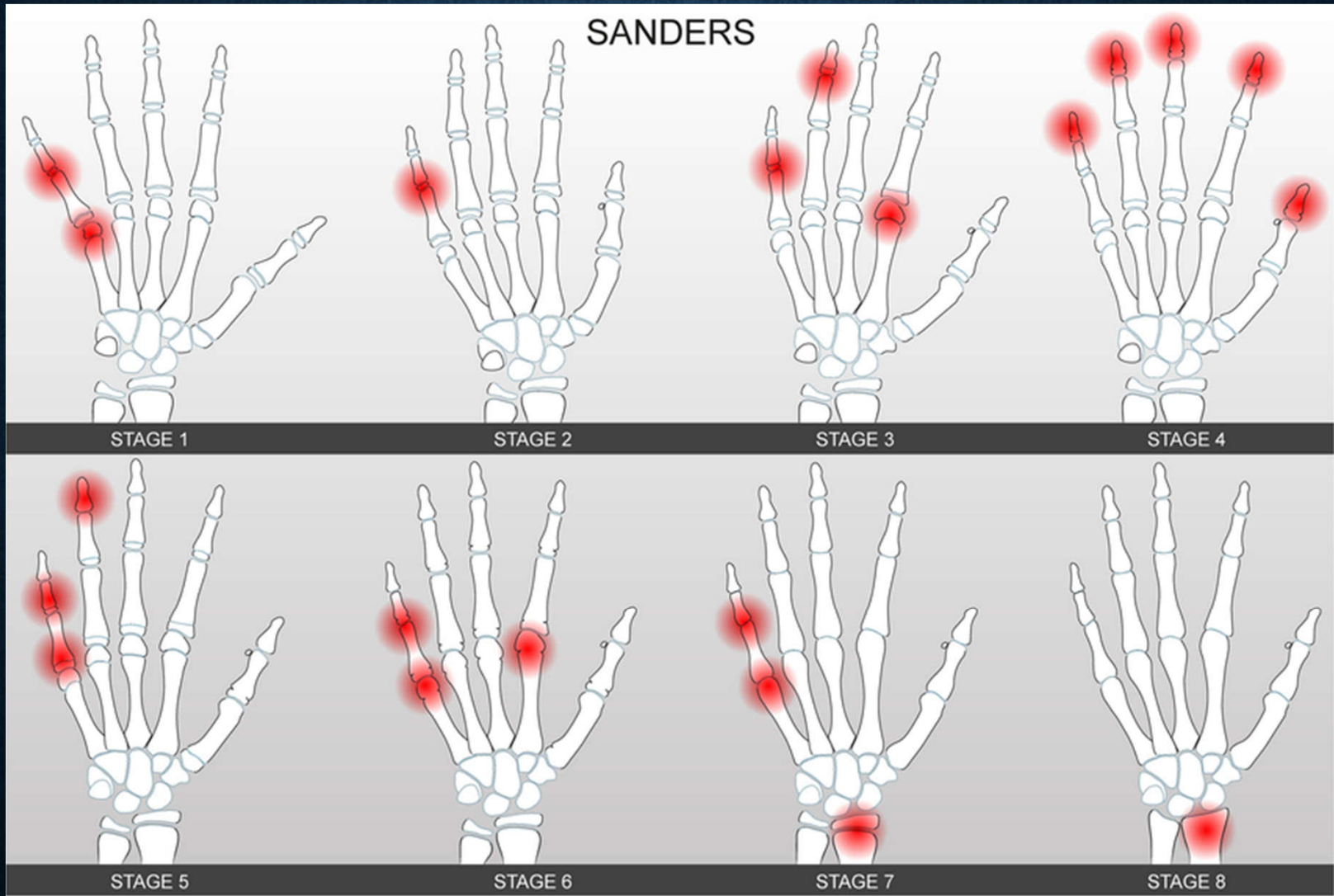




Chron. Age	Std Dev.	2x Std. Dev
9 years	9.00	18.00
10 years	9.79	19.58
11 years	10.09	20.18
12 years	10.38	20.76
13 years	10.44	20.88

## Female: 11 Years




Chron. Age	Std Dev.	2x Std. Dev
9 years	10.74	21.48
10 years	11.73	23.46
11 years	11.94	23.88
12 years	10.24	20.48
13 years	10.67	21.34





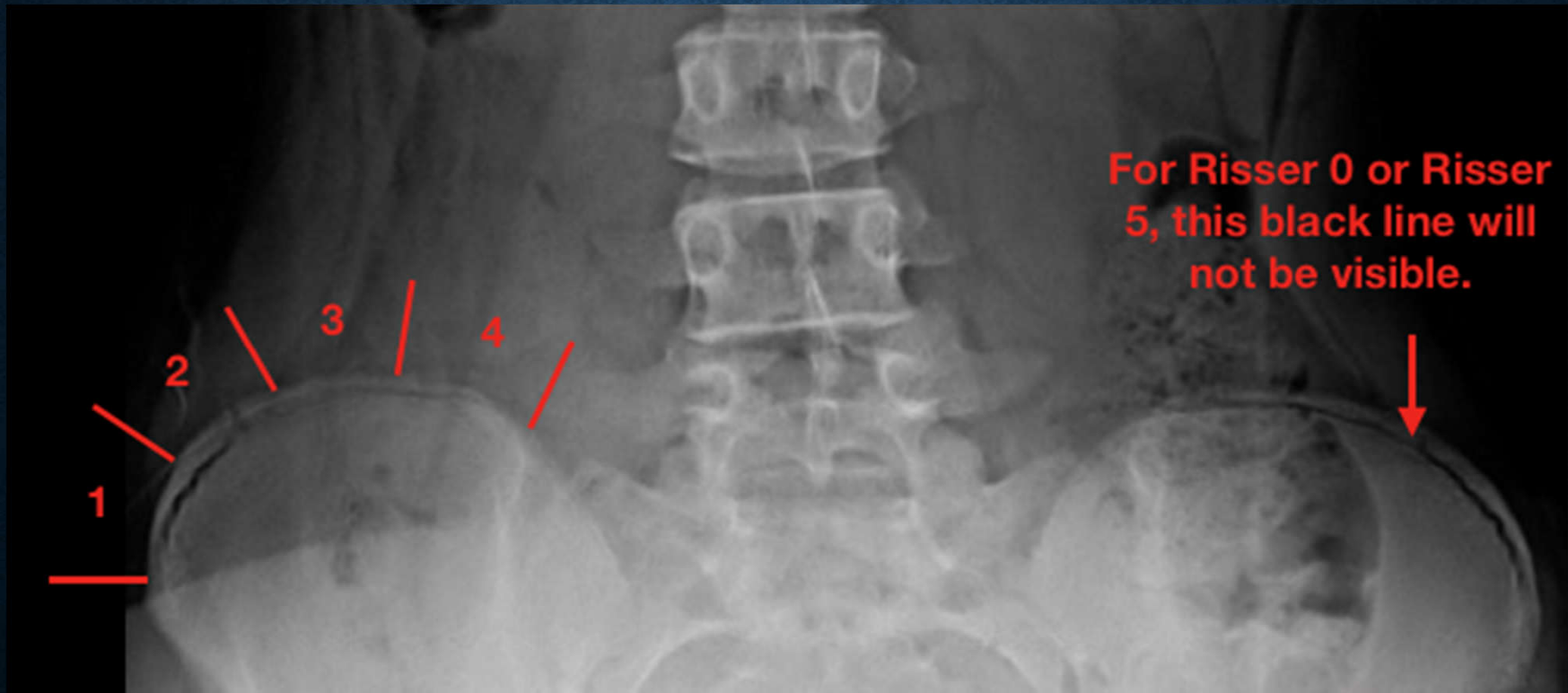
**Table 2.** Exposure chart for commonly performed paediatric general radiography procedures at RCH. Shaded cell indicates exam performed with grid. Source to detector distance 100 cm out of bucky, 110 cm with grid and or in bucky (chest radiographs at 125 cm).


Exam	kVp Range	mAs					
		3-7 kg	8-15 kg	16-25 kg	26-40 kg	41-60 kg	60+ kg
Chest AP †/PA ‡	70-90	0.71	0.8	1	1.2	1.4	2













<b>WOMEN'S IMAGING</b> 	Procedure	Approximate effective radiation dose	Comparable to natural background radiation for:					
		Bone Densitometry (DEXA)	0.001 mSv	3 hours				
	Shoulder AP	55-65	1	1.4	2	4	10	14
	Shoulder Lateral	60-70	1.6	2	3	4	14	18
	Humerus AP	55-65	1.2	1.4	1.6	2	2.5	3
	Forearm AP	52-55	1	1.4	1.6	2	2.5	3
	Hands AP	50-55	1	1.2	1.2	1.4	1.6	2

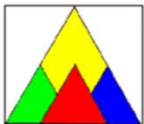


## THE RISSER STAGING SYSTEM





Risser+	Ossification of Tri-riate Cartilage	US Classification	French (European) Classification
0-	not yet 	0	0
0	ossified 	0	0
1 (0-25%)		1 (0-25%) 	1 (ossification begins) 
2 (25%-50%)		2 (25%-50%) 	2 (partially fused) 
3 (50-75%)		3 (50-75%) 	
3-4 (75-100%)		4 (75-100%) 	3 (cover completely) 
4 (fusion begins)			4 (fusion begins) 
5 (complete fusion)		5 (100%) 	5 (fusion complete) 



## Case Series

# Two for One: A Change in Hand Positioning During Low-Dose Spinal Stereoradiography Allows for Concurrent, Reliable Sanders Skeletal Maturity Staging

Taylor J. Jackson, BA<sup>a</sup>, Daniel Miller, MD<sup>a</sup>, Susan Nelson, MD, MPH<sup>a</sup>, Patrick J. Cahill, MD<sup>a,b</sup>,  
John M. Flynn, MD<sup>a,b,\*</sup>

<sup>a</sup>*Division of Orthopaedics, Children's Hospital of Philadelphia, 3401 Civic Center Blvd, Philadelphia, PA 19104, USA*

<sup>b</sup>*The Perelman School of Medicine, University of Pennsylvania, Philadelphia, PA 19104, USA*

Received 25 July 2017; revised 4 January 2018; accepted 7 January 2018

### Abstract

**Study Design:** Prospective survey.

**Objectives:** To evaluate the reliability of low-dose stereoradiography compared to standard hand bone age films for assessing Sanders skeletal maturity stage in patients with idiopathic scoliosis.

**Summary of Background Data:** The Sanders skeletal maturity staging system is a valuable tool in the care of juvenile and adolescent spine scoliosis, but obtaining dedicated hand films adds additional time, radiation, and expense to the clinic visit. A change in patient hand positioning for routine full-length PA spine low-dose stereoradiography may offer a viable alternative.

**Methods:** A survey consisting of 30 standard bone age hand films and 26 posteroanterior spine low-dose stereoradiography images (magnified view of hands only) was created in REDCap and distributed to two pediatric spine surgeons and two fellows. The graders were asked to classify the images according to the Sanders skeletal maturity classifications. Images were graded in two trials conducted one week apart. Inter- and intraobserver reliability was assessed using the mean linearly weighted kappa to provide an overall index of agreement.

**Results:** In Trial 1, the interobserver reliability was similar for both the standard bone age films ( $\kappa = 0.82$ ) and for the low-dose stereoradiography films ( $\kappa = 0.79$ ) ( $p = .501$ ). In Trial 2, reliability was similar between imaging modalities and slightly improved for both standard bone age films ( $\kappa = 0.85$ ) and low-dose stereoradiography films ( $\kappa = 0.82$ ) ( $p = .192$ ). Intraobserver reliability was strong for both standard films ( $\kappa = 0.89$ ) and low-dose stereoradiography films ( $\kappa = 0.86$ ) ( $p = .446$ ).

**Conclusion:** A simple change in patient hand positioning for low-dose stereoradiography allows clinicians to simultaneously assess a patient's spinal deformity and skeletal maturity with excellent reliability. Given the frequency of scoliosis surveillance visits, this simple change could lead to significant savings of time, money, and radiation exposure for the growing child.

**Level of Evidence:** Level III.

© 2018 Scoliosis Research Society. All rights reserved.

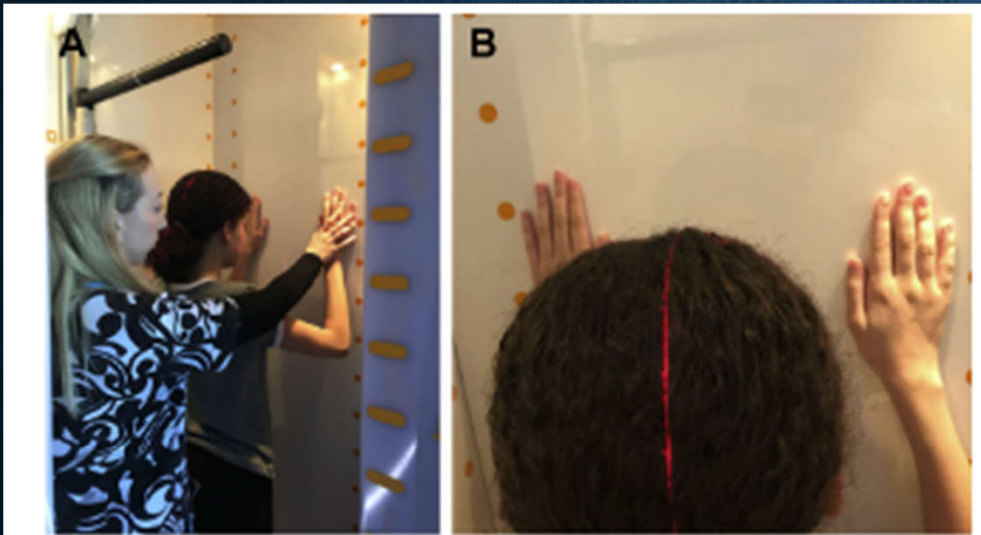
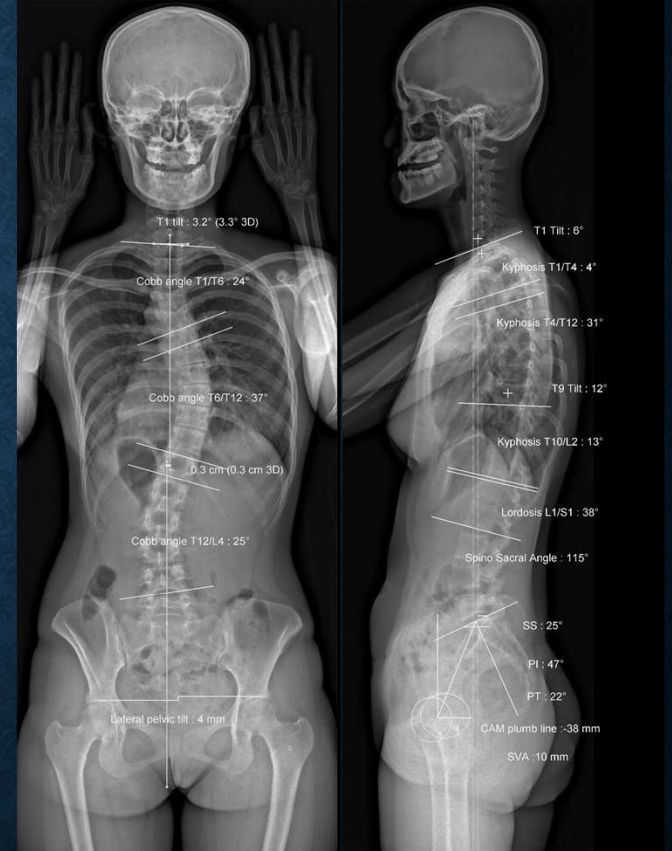


Fig. 1. (A) A radiology technicians demonstrating proper hand positioning, confirmed by standing behind the patient and sighting the wrists just above the shoulders. (B) The hand should be inside the orange dots on the stereoradiography machine.



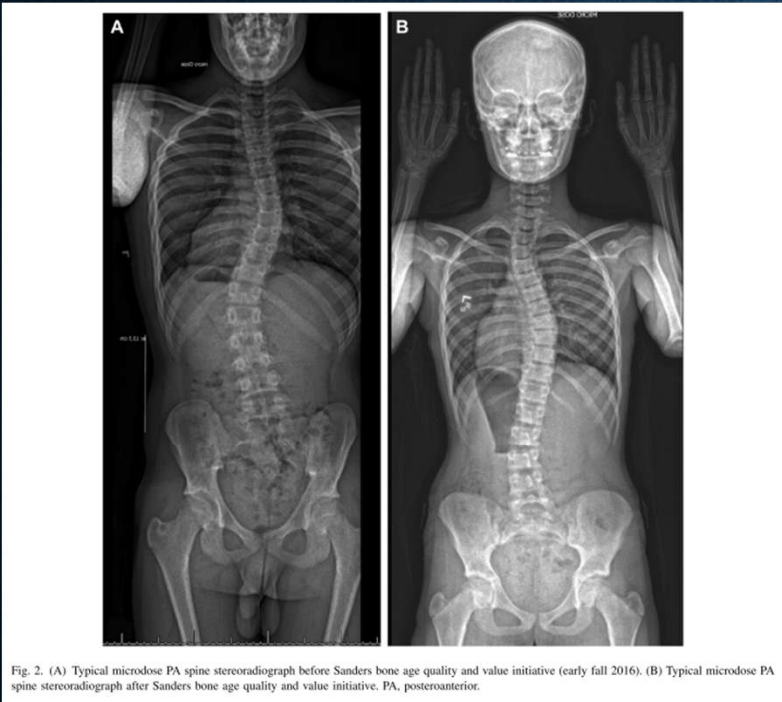

Fig. 2. (A) Typical microdose PA spine stereoradiograph before Sanders bone age quality and value initiative (early fall 2016). (B) Typical microdose PA spine stereoradiograph after Sanders bone age quality and value initiative. PA, posteroanterior.


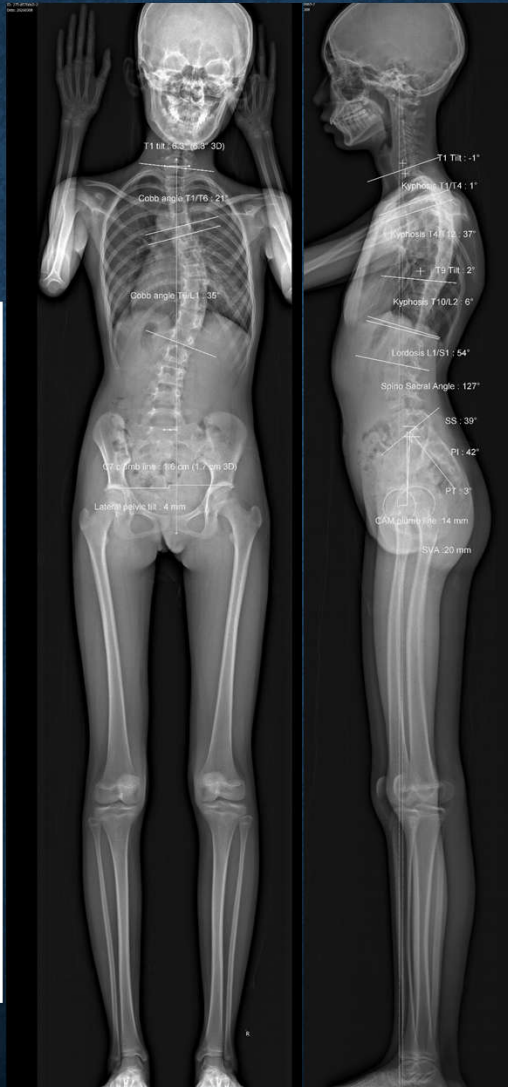

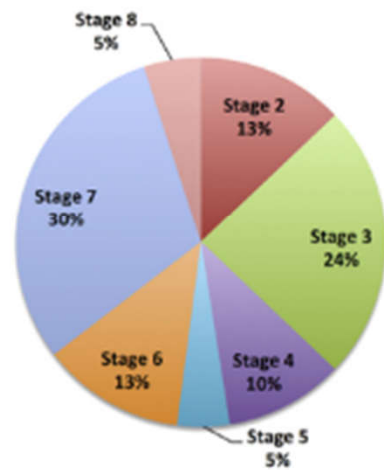


Table 4  
Summary of absolute agreement.

	Standard hand bone age			Stereoradiography		
	Stage 4 or less, %	Stage 4 or greater, %	All, %	Stage 4 or less, %	Stage 4 or greater, %	All, %
<b>Interobserver</b>						
Perfect agreement	27	50	38	17	39	29
Within one stage	87	100	93	58	93	77
<b>Intraobserver</b>						
Perfect agreement	60	90	76	47	84	68
Within one stage	98	100	99	88	100	95

Distribution of Assigned Skeletal Maturity Scores – Standard Radiographs



Distribution of Assigned Skeletal Maturity Scores - Stereoradiographs

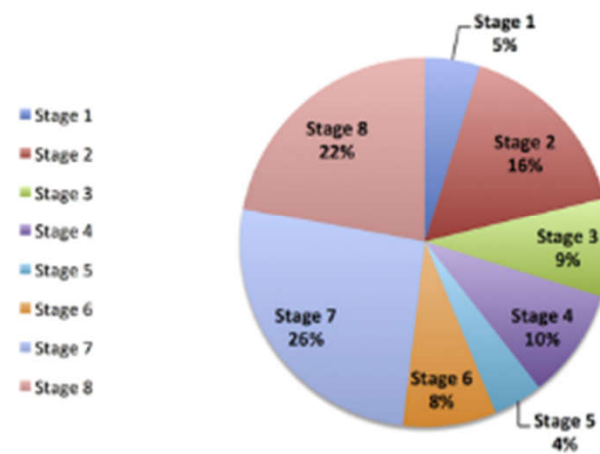


Fig. 3. The distribution of assigned skeletal maturity score for the standard hand bone age radiographs and stereoradiographs.



TÀI LIỆU THAM KHẢO:

1. R.M. CAMPBELL JR., M.D. SMITH, THORACIC INSUFFICIENCY SYNDROME AND EXOTIC SCOLIOSIS, J BONE JOINT SURG AM, 89 (SUPPL 1) (2007), PP. 108-122
2. DEVELOPMENT OF A TREATMENT MATRIX FOR ADOLESCENT IDIOPATHIC SCOLIOSIS (IS), BY [LUHMANN](#) • APRIL 19, 2023
3. *BONE+AGE+BOOK.PDF*
4. *TWO FOR ONE: A CHANGE IN HAND POSITIONING DURING LOW-DOSE SPINAL, STEREORADIOGRAPHY ALLOWS FOR CONCURRENT, RELIABLE SANDERS SKELETAL MATURITY STAGING*, TAYLOR J. JACKSON, BAA, DANIEL MILLER, MDA, SUSAN NELSON, MD, MPHA, PATRICK J. CAHILL, MDA,B, JOHN M. FLYNN, MDA,