

Endoscopy symposium



9/10
10/4/26
Đạt
Kính gửi
Thư mời

Thư mời

**HỘI THẢO KHOA HỌC
CẬP NHẬT TIẾN BỘ CỦA NỘI SOI
TRONG CHẨN ĐOÁN VÀ ĐIỀU TRỊ U ỚNG TIÊU HÓA**

SCIENTIFIC CONFERENCE

**UPDATES ON ADVANCED ENDOSCOPY IN THE DIAGNOSIS
AND MANAGEMENT OF GASTROINTESTINAL NEOPLASMS**

08:00 - 16:00 - Ngày 15 tháng 04 năm 2025
Hội trường Lầu 8 - Khu Kỹ thuật cao

Kính gửi:

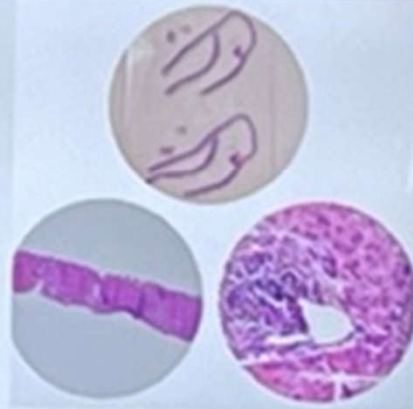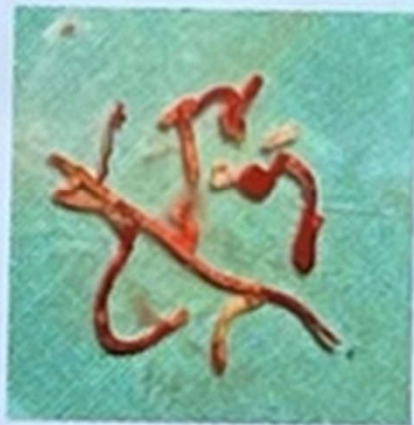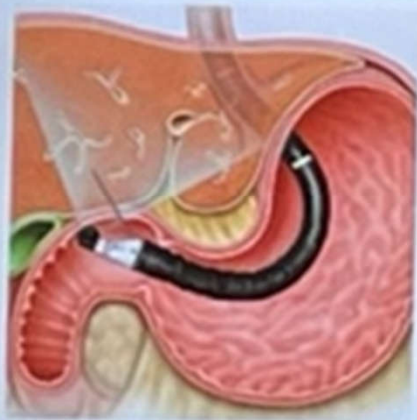TRUNG TÂM Y KHOA MEDIC

1x

2



TỔ CHỨC MỌI THẮNG LỢI



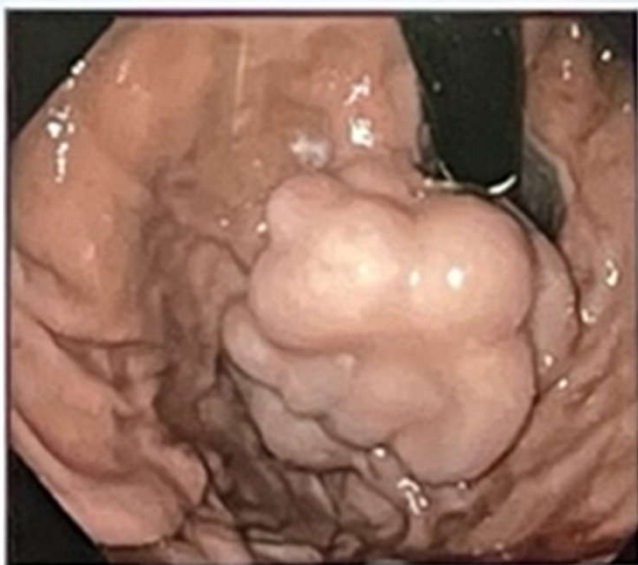Sinh thiết gan

- Sinh thiết dưới hướng dẫn EUS
- Doppler: giảm tỷ lệ chảy máu

TO CHỨC MỌI THẮNG LỢI

Nguyên tắc đặt coil dưới hướng dẫn EUS

- Tạo khung cơ học
- Kích ứng thuyên tắc
- Giảm dòng chảy
- Tăng giữ keo (histoacryl)



MỌI THẮNG LỢI

Nội dung

01

Nội soi siêu âm (EUS) trong bệnh lý ống tiêu hóa

02

Nội soi siêu âm trong bệnh lý mật - tụy

03

Nội soi siêu âm trong bệnh lý gan

04

Kết hợp ERCP-EUS trong tình huống lâm sàng đặc biệt

Take-home summary



Pancreas

- EUS-guided PFC/WON drainage
- EUS-FNB is standard;
- EUS-RFA is emerging as a minimally invasive therapy for selected pNETs and possibly pancreatic cancer.



Liver

- EUS-LB and EUS-PPG are reshaping the assessment of diffuse liver disease and portal hypertension
- Enabling combined diagnostic and therapeutic "endo-hepatology" procedures.



Biliary system

- EUS-BD, digital cholangioscopy and endobiliary RFA are transforming the management of indeterminate strictures, difficult stones, and malignant biliary obstruction.

UPDATES ON ESD FOR TREATMENT OF EARLY COLORECTAL CANCER



PHAM CONG KHANH, MD, PhD

Tam Anh General Hospital in Ho Chi Minh city

OUTLINE

Introduction

Indications of colorectal ESD






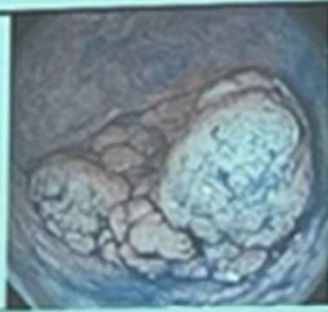

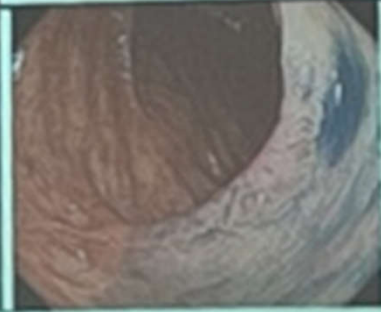
Evaluation before ESD

Basic and advanced ESD techniques




Complications and prevention

Outcomes of colorectal ESD









Conclusion















Granular		Non-Granular	
Homogenous	Nodular mixed	Flat elevated	Pseudo-depressed
			
			

NICE

	Type 1	Type 2	Type 3
Color	Same or lighter than background	Browner relative to background (very color arises from vessels)	Brown to dark brown relative to background, sometimes patchy whitish areas
Vessels	None, or isolated lacy vessels may be present coursing across the lesion	Brown vessels surrounding white structures ^{***}	Has area(s) of disrupted or missing vessels
Surface pattern	Dark or white spots of uniform size, or homogeneous absence of pattern	Oval, tubular or branched white structures ^{***} surrounded by brown vessels	Amorphous or absent surface pattern
Most likely pathology	Hyperplastic & sessile serrated polyp (SSP) ^{***}	Adenoma ^{****}	Deep submucosal invasive cancer
Endoscopic image			

JNET

NBI	Type 1	Type 2A	Type 2B	Type 3
Vessel pattern	Irregular **	Regular pattern Regular distribution Irregular pattern (artery) [†]	Variable pattern Irregular distribution	Linear vessel pattern Interruption of thick vessels
Surface pattern	Regular dark or white areas Similar to surrounding normal mucosa	Regular Subarboriform (capillary)	Irregular or obscure	Amorphous areas
Most likely histology	Hyperplastic polyp (sessile serrated lesion) ^{††}	Low grade intramucosal neoplasia	High grade intramucosal neoplasia ^{†††} Submucosal invasive cancer ^{††††}	Deep submucosal invasive cancer
Endoscopic image				
				

I		Round pit (normal pit)	
II		Asteroid pit	
III _s		Tubular or round pit that is smaller than the normal pit (type I)	
III _l		Tubular or round pit that is larger than the normal pit (type I)	
IV		Dendritic or gyrus-like pit	
V _i		Irregular arrangement and sizes of III _l , III _s , IV type pit pattern	
V _N		Loss or decrease of pits with an amorphous structure	

KUDO

- Tumor – non tumor: 96–98%
- Adenoma – cancer: 70–90%

INTRODUCTION

Endoscopic submucosal dissection (ESD), a widely established endoscopic modality

- First developed in Japan
- Increasingly performed in Asia, Europe, and the United States

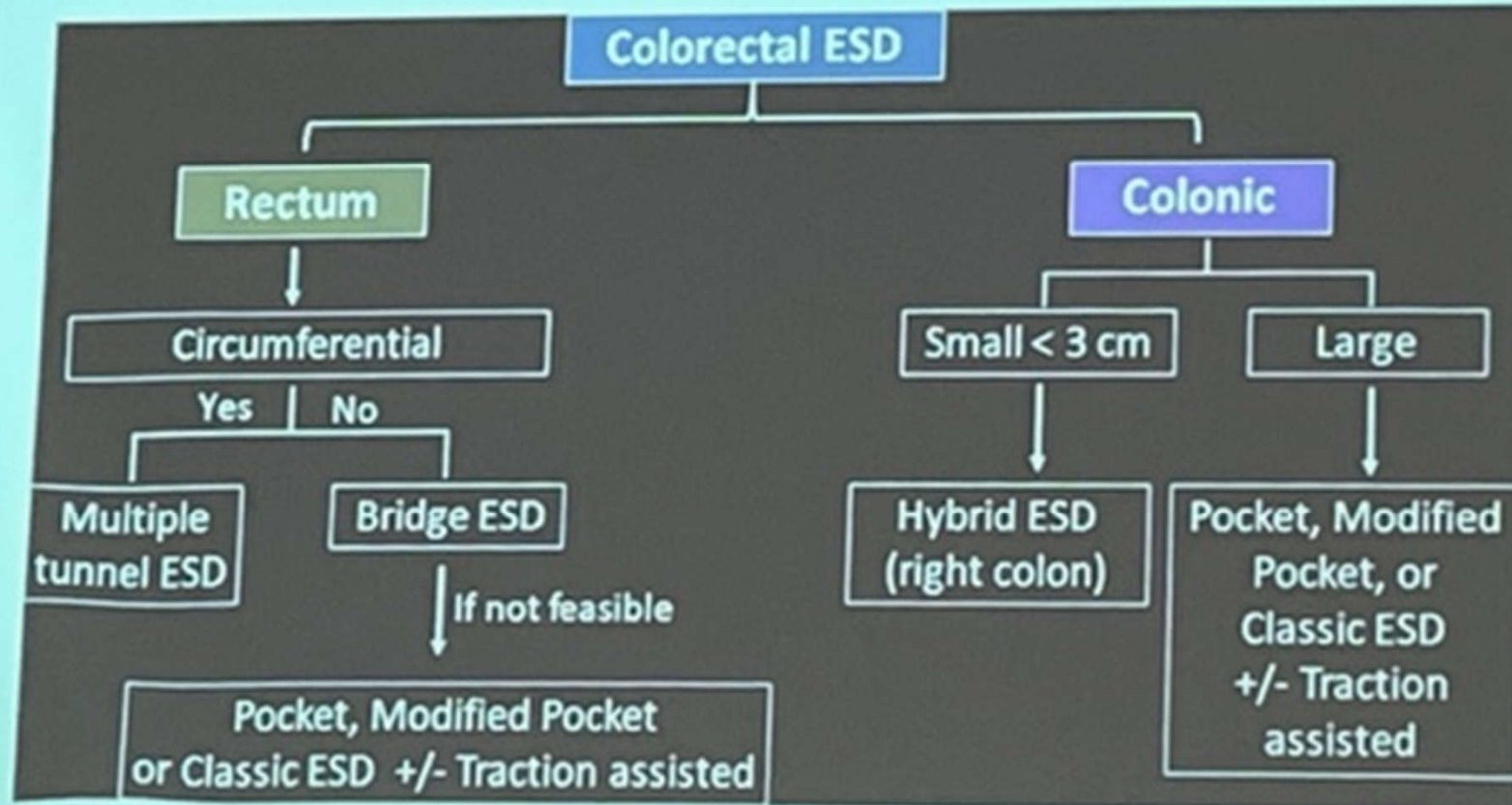
ESD be safely performed in the esophagus, stomach, duodenum, and colorectum.

ESD

- En bloc removal of large superficial lesions
- Reduces the risk of local recurrence
- Precise pathological evaluations
- An organ-sparing procedure

Qatomah, A., & Aihara, H. (2025). *DEV open*, 5(1), e394.

Ge, P. S., & Aihara, H. (2022). *Digestive diseases and sciences*, 67(5), 1521-1528.



Summary

Early digestive cancer detection: high magnification endoscopy

Endoscopic treatment: EMR or ESD

Third space endoscopy(TSE): ESD, POEM, STER

EUS: endosonography supports endoscopy in diagnosis & treatment especially in ERCP